

# We are IntechOpen, the world's leading publisher of Open Access books Built by scientists, for scientists

4,600

Open access books available

119,000

International authors and editors

135M

Downloads

Our authors are among the

154

Countries delivered to

TOP 1%

most cited scientists

12.2%

Contributors from top 500 universities



WEB OF SCIENCE™

Selection of our books indexed in the Book Citation Index  
in Web of Science™ Core Collection (BKCI)

Interested in publishing with us?  
Contact [book.department@intechopen.com](mailto:book.department@intechopen.com)

Numbers displayed above are based on latest data collected.  
For more information visit [www.intechopen.com](http://www.intechopen.com)



# Applications of CBCT in Endodontics

*Jesús Mena Álvarez and Álvaro Zubizarreta Macho*

## Abstract

There are many articles published in recent years on the use of CBCT in endodontics and this diagnostic technique is increasingly required in order to have a more accurate prognosis of the teeth to be treated. The purpose of this chapter is to discuss the use of Conical Beam Computed Tomography (CBCT) in the field of endodontics. This issue is controversial at the moment because of the increase in the radiation to which patients are being subjected; however, we know that sometimes the X-rays taken with different angles in relation to some teeth depending on the different cases are incompatible in form and density, which does not allow us to make an exact diagnosis. The use of CBCT would have provided an image of greater diagnostic value in those cases. In addition, the use guidelines published by the American Endodontics Association and the American Radiology Association jointly mark the way forward and the use we can give the CBCT for the diagnosis of complex cases.

**Keywords:** CBCT, endodontics, tomography, root canal treatment

## 1. CBCT description

CBCT is the technique that allows three-dimensional reconstruction, but using a conical beam to decrease the dose for the patient compared to conventional CT. For almost a century, dentists have been studying a 2D representation of a 3D structure, that structure is the tooth. This simplification of the information produces inherent disadvantages, among which the anatomical structures in the plane of the roots and apices of the teeth studied mask many details, which occur mainly in the area of the upper molars, where the zygomatic arch or the breast can complicate the detail of the posterior anatomy of the roots of the teeth, which entails a complicated diagnosis and treatment [1]. In practice this means that radiolucent areas may not be identified, being able to find difficulties in relating the position of the apex in proximity to vital structures and not being able to detect the exact situation of the calcifications of the teeth. The correct identification of the morphology and anatomy of the root canals can be difficult, as well as the identification of root fractures and root resorption [2].

We can rule out a series of milestones in the history of CBCT and radiology beginning in 1895 when Wilhelm Roentgen discovered X-rays in Germany, but it is not until 1896 when the first intraoral radiography is performed by Edmond Kells in New Orleans. Already in 1967 Godfrey Hounsfield developed the first CT scanner and in 1971 it was introduced in medical examination. In 1990 Tachibana and Matsumoto reported the first use of CT in endodontics and in 1997 Quantitative

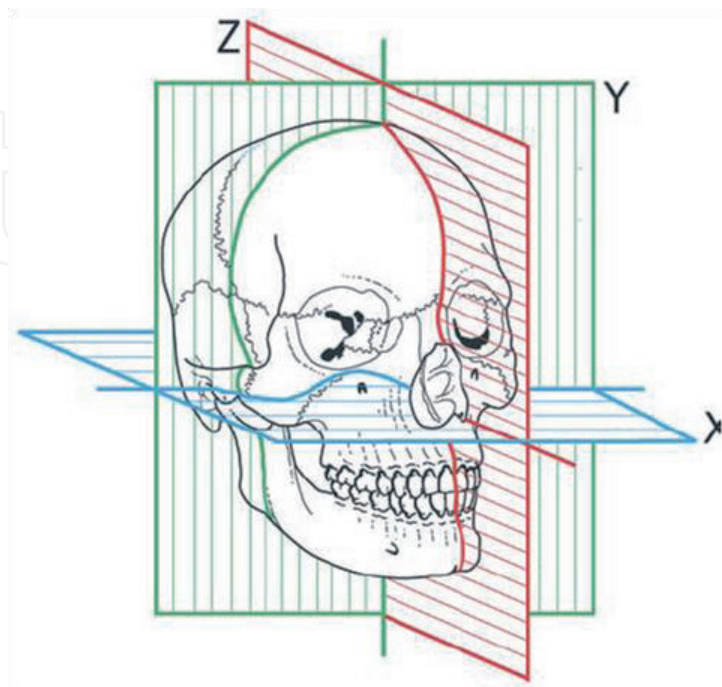
Radiology produced the first CBCT, the New Tom 9000, for dental use after Arai's pioneering work in Japan and in Mozzo in Italy, obtaining in 2001 the first CBCT licensed for use in the US [3].

## 2. How does a CBCT work?

The process begins with an emitter that directs a very fine beam of X-rays through a collimator (system that from a divergent beam forms a parallel beam). This beam affects the object under study which is crossed or irradiated by a percentage of lightning. This radiation, which has not been absorbed by the object, in the form of a spectrum, is collected by detectors. The detectors depending on the CBCT are of different materials, they can be silicon or selenium or a CCD sensor (digital analog converter) the X-ray source and the detector are connected in such a way that they have a synchronous movement.

The function of the CCD sensor is to convert the information obtained from analog to digital that transforms the electrical signal produced by the interaction of the detector with the patient's emerging X-rays, into a binary signal suitable for processing by software specially designed for each brand of CBCT.

The source-detector assembly rotates and performs the X-ray shot, obtaining a projection or cut of the tooth under study. The team performs several rotations to obtain 360 images or cuts corresponding to each degree of rotation that are reconstructed, thus achieving a three-dimensional image of the skull. This 2D data is then converted through conical beam algorithms [4] into a 3D volume of data for a PC in any of the 3D planes or a 3D image. Normally, transverse images are generated in the three orthogonal planes from the CBCT scan. The professional selects the position and thickness of the cut inside the data volume. The three views can be evaluated simultaneously, since the modification of the cut in one of the planes modifies the rest of the planes displayed. This can be manipulated by PC software to provide more detail of specific areas of interest [5].



**Figure 1.**  
*Illustration of the 3-dimensional planes.*

Sagittal plane: Perpendicular to the ground and parallel to the middle sagittal plane, which divides the body into left and right halves (Z).

Axial plane: Perpendicular to the longitudinal axis of a body (X).

Coronal plane Divide the skull into a ventral part and another dorsal part (Y) (**Figure 1**).

Axial and proximal views are of particular value since they are generally not seen on a conventional periapical radiograph [6].

Thanks to the cone-beam technology and algorithmic calculations it is possible to overcome the distortions produced by the patient's breathing [7].

### **3. Essential CBCT concepts related to endodontics**

The most important concepts in the use of CBCT in endodontics are the field of vision and the spatial resolution of the machine.

The visual field to be studied or Field of View (FOV) is directly related to the area to be scanned which will be digitally represented on the computer. The FOV measurement for face studies in dentistry with conical beam tomography is 14 cm. what determines the quality of the tomographic image (the size of the pixel and the voxel) is the division between FOV and the matrix. Roughly speaking, CBCT systems can be classified into two categories: limited (dental or regional) or complete (ortho or facial). The limited range FOV is 40–100 nm, while the field of view of the full range is 100–200 nm. A typical FOV consists of millions of voxels [8].

In endodontics, the FOV can be small or “focused” (5 cm by 5 cm or less) because the root canal treatment generally involves one tooth in an arch. This reduction in FOV reduces the amount of effective radiation dose [9]. Other advantages of a small FOV field of view are decreased time to process and read the image, better ability to avoid metallic structures that can cause interference, greater spatial resolution and improved diagnostic potential [10]. Most small FOV machines produce an effective radiation dose in the same order of magnitude as a panoramic radiograph or a periapical series [11].

The degree of spatial resolution is determined by the voxel size, it is desirable that the resolution of a CBCT machine used for endodontics should not exceed 200  $\mu\text{m}$ , the average width of the periodontal space. Otherwise no pathological changes will be identified.

### **4. Uses of small-field CBCT in endodontics**

Possible applications in endodontics include the diagnosis of endodontic pathology and its origin, root canal system morphology, root evaluation (fractures and traumas), analysis of external or internal root resorption, invasive cervical resorption, presurgical planning, lesion extension, complicated anatomies, location of calcified root canals, endodontic retreatment, evaluation of iatrogenies such as perforations, separate instruments or extrusion of sealing material [12–14].

#### **4.1 Definitive diagnosis of the periapical radiolucent areas**

Endodontic treatment aims to preserve the tooth with normal function and prevent or cure apical periodontitis. However, periapical radiographs provide a two-dimensional view of a three-dimensional object. Therefore, periapical radiographs cannot detect lesions such as apical periodontitis confined within the spongy bone.



Bender et al. in 1961 demonstrated in vitro that bone lesions cannot be diagnosed effectively by X-rays unless cortical bone is perforated [15, 16].

Goldman et al. showed that there was considerable disagreement among professionals in the diagnosis of radiolucent areas with radiographs. The reasons for these inconsistencies are the 2D nature of the radiographic image and anatomical distortion that can mislead the professional. Increasing the number of X-rays, taken at different angles improves diagnostic accuracy [17].

Conical beam tomography results in 3D images that eliminate the overlap of anatomical structures. The use of CBCT helps detect periapical radiolucent lesions or areas and make a differential diagnosis with a non-invasive technique that is very accurate (Figure 2).

According to Levin et al., the etiology of irreversible pulpitis could be caries or deep restorations, pulp exposure, cracks or any irritating pulp among others [18]. Radiographic visualization of teeth with irreversible pulpitis on conventional periapical radiographs can be normal except for the presence of the etiological cause. Occasionally, if the inflammatory process has spread to the periapical area, a thickening of the periodontal ligament space may be visible [12].

However, the use of 2D radiography still has serious limitations. The studies carried out by Estrela et al. in 2008 evaluated apical periodontitis (AP) in 1508 teeth by 3 methods (panoramic, periapical radiographs and CBCT) concluded that the diagnostic accuracy was significantly higher with periapical radiographs (54.5%) than with panoramic radiographs (27.5%) using the CBCT as a gold standard reference about diagnostic accuracy; apical periodontitis was correctly identified with conventional radiography only when it was sufficiently advanced. Estrela concluded that prevalence of AP was significantly higher with CBCT, overall sensitivity was 0.55 and 0.28 for periapical and panoramic radiographs, respectively and AP was correctly identified with conventional methods when showed advanced status. CBCT was proved to be accurate to identify AP [19].

Lofthag Hansen in 2007 compared the periapical state of 46 maxillary and mandibular molars with two angled periapical radiographs and CBCT scans. CBCT detected 38% more lesions than periapical radiographs [20]. Low et al. in 2008 [21] and Cotton et al. [22] in 2007 give us similar results. García-Silva de Paula in 2009 with an in vivo study examined the periapice of 83 teeth in dogs

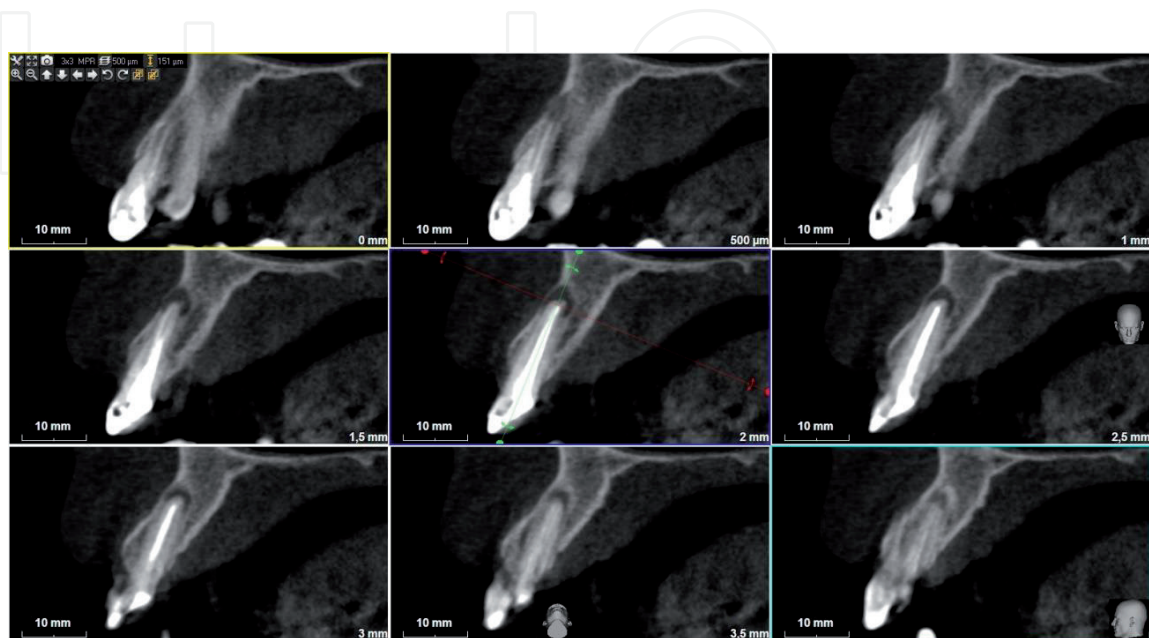


Figure 2.  
Images of the CBCT scan.

with periapical radiography and CBCT using histological examination as a gold standard and the conclusions were that CBCT diagnosed healthy areas more accurately than radiography and was more sensitive in detecting apical periodontitis (AP). The AP was detected in 71% of roots with radiography, 84% with CBCT and 93% with histology [23, 24].

#### **4.2 Visualization of root fractures**

Vertical root fractures (VRF) are a type of fractures that extend along the major axis of the tooth. If the diagnosis is not carried out, progressive destruction of the periodontal ligament and alveolar bone occurs which can influence the prognosis of adjacent teeth and future restorations. However, VRF may not produce any signs or symptoms such as pain or discomfort from chewing. Therefore, it is important that VRFs be diagnosed as quickly as possible. The prevalence of VRFs in several populations has been reported between 2 and 5% and depending on the literature reviewed; the percentage of endodontic and fissured teeth varies between 3 and 30%. The highest incidence occurs between 40 and 60 years [25]. The most common teeth where it occurs are lower molars and upper premolars [26]. One third of the VRFs are radiographically detectable, usually when the beam is perpendicular to the fracture line or the granulation tissue separates fragments [27]. (**Figure 3a and b**).

Mesio-distal fractures are almost impossible to detect with normal radiography [28]. The most effective in vivo diagnostic method of an LRF is surgical exposure of the fracture, and visual inspection under magnification with the help of staining. Edlund et al. examined 32 teeth in 29 patients, which gave symptoms of a VRF, with CBCT and subsequent surgical exploration; the results showed a high correlation between the diagnosis through CBCT and direct visualization, which confirms numerous in vitro studies that support the validity of CBCT in the diagnosis of VRF [29].

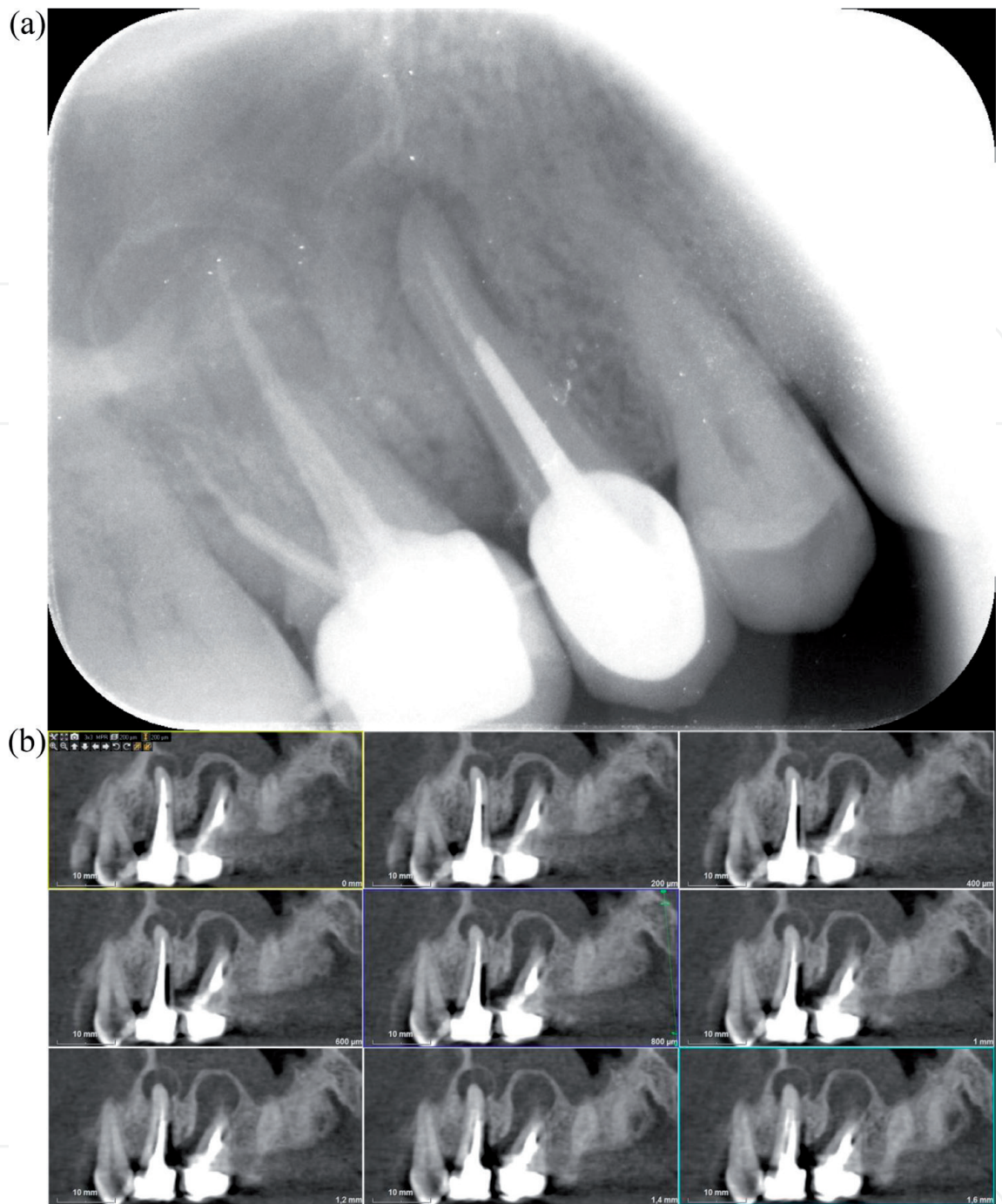
#### **4.3 Diagnosis and treatment of dento-alveolar trauma**

Most maxillofacial traumatic injuries involve only teeth (50%) or teeth and adjacent soft tissue (36%) while those affecting the alveoli are 13.6% remaining [30]. Unfortunately, periapical radiography has low sensitivity for the diagnosis of minimal displacements of teeth, alveolar or root fractures, however CBCT has the advantage that it is more comfortable for the traumatized patient; extraoral scan generates a multidimensional image avoiding the need for multiple intraoral radiographs. Bernardes et al. in 2009 compared, retrospectively, conventional periapical radiographs and CBCT images in 20 patients with suspected root fractures and found that CBCT was able to detect fractures in 90% of patients, while radiography could only detect fractures in 30–40% of patients. In conclusion, they reported that CBCT was an excellent complement to conventional radiography in the diagnosis of root fractures [31].

#### **4.4 Identification of the apices of the teeth in relation to anatomical structures**

Conventional radiographs do not always allow for the evaluation of the spatial relationship of roots with their surrounding anatomical structures [32]. This is important in the context of surgical planning and treatment [21]. Radiological identification of the position of the roots and their apices against structures vitals such as the maxillary sinus or the dental canal is essential for pre-surgical evaluation for endodontic microsurgery and to prevent injury during root canal filling. Velvart et al. studied 55 patients with 44 lower molars and 6 lower premolars, which had been referred for apical surgery due to persistent periapical areas.

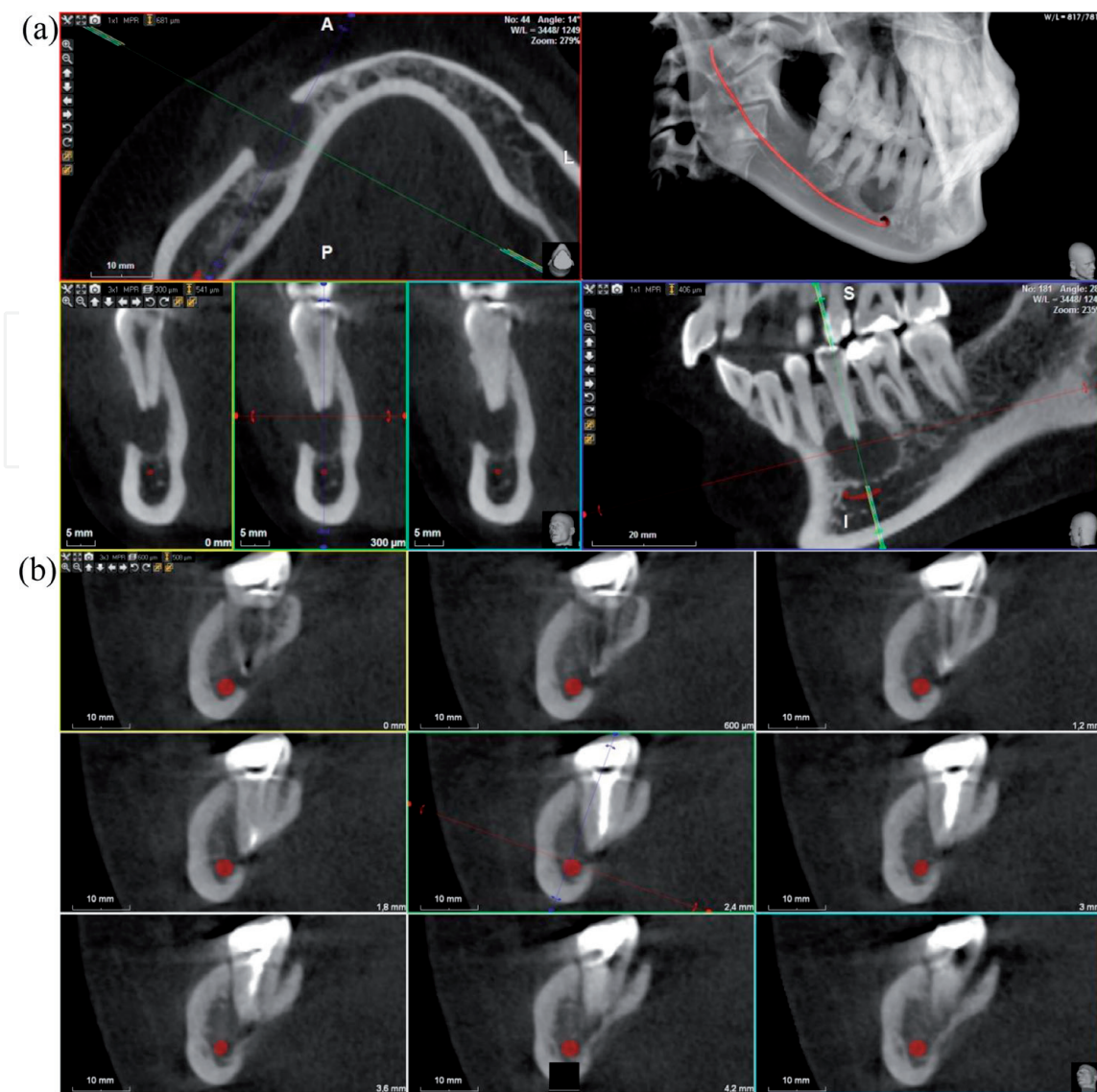




**Figure 3.**  
 (a) Periapical radiography and (b) CBCT scan of the same lesions.

CBCT and periapical radiography were performed to identify these lesions, and concluded that the root canal system could be identified in 3 cases with normal radiography, but it was identified in all cases with CBCT and CBCT was also able to quantify the amount of cortical and spongy bone and the three-dimensional extent of the lesion [33]. (**Figure 4a and b**).

Rigolone et al. studied 43 upper first molars using CBCT for a possible microsurgical treatment of the palatine root and concluded that this method could provide enough information for a minimally invasive microsurgical technique through a vestibular access instead of a palatal access approach [34]. Low et al. in 2008 evaluated 37 premolars and 37 molars, derived for endodontic surgery in the upper jaw and verified that CBCT was able to identify 34% more lesions than periapical radiography; this detection was influenced by the proximity of the apices to the floor of the maxillary sinus and it was more difficult in



**Figure 4.**  
*The CBCT scan allows a diagnosis and treatment plan in all planes. (a) Sagittal view and (b) Coronal view.*

upper second molars. CBCT was also able to identify sinus membrane thickening, expansion of lesion in maxillary sinus, and apico-marginal communications while periapical radiographs not. These are important pre-surgical markers that may indicate possible surgical complications, oral antral fistula and vertical root fracture [21].

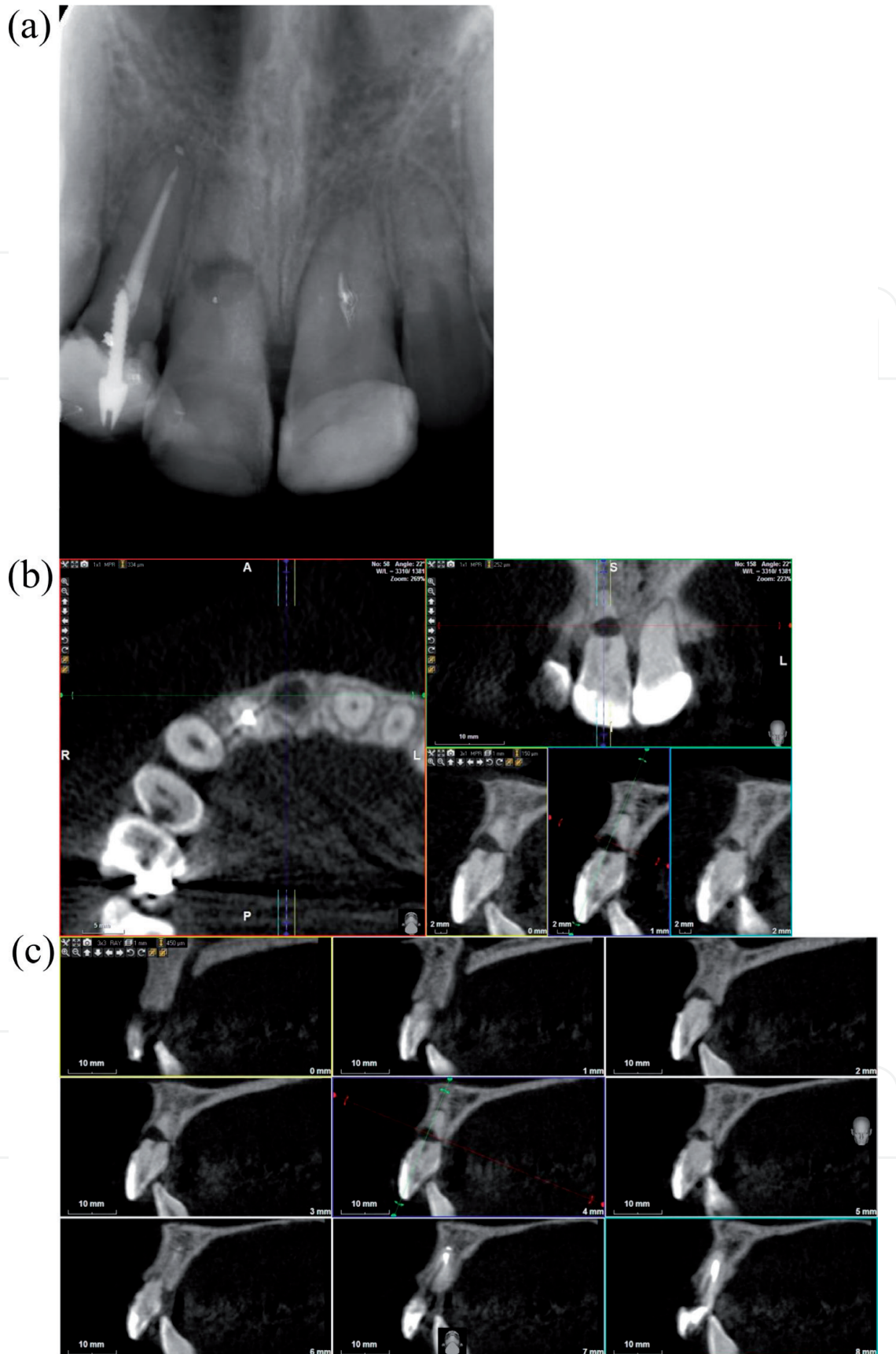
#### 4.5 Identification of root resorption

Root resorption is the loss of dentin or cement as a result of osteoclastic activity. The resorption can be classified according to its location in internal or external. The cells responsible for resorption, whether internal or external, have been described as osteoclasts, odontoclasts and dentinoclasts.

Internal root resorption occurs exclusively as a result of pulp inflammation. Until very recently, the diagnosis of internal or external resorption defects has been limited to the information obtained from conventional radiography techniques. Currently, the use of CBCT is used in the planning of diagnosis and treatment of a case of resorption [35]. (**Figure 5a, b and c**).

Accurate identification is essential to ensure both correct treatment and management as it differs depending on the type of resorption. Gartner et al. described the guidelines to differentiate the types of resorption and the use of





**Figure 5.**  
*(a) Periapical radiography of teeth affected by a root resorption, (b and c) CBCT scan of the teeth affected by a root resorption.*

2D radiographic techniques with a parallelizer was postulated as the method to differentiate internal resorption from external. However, conventional radiography does not represent the lesion, being unable to identify its true size,

location and access [36]. The diagnostic advantages of CBCT lie in the ability of its software to access the most favorable orthogonal views related to the specific spatial vision and the ability to reproduce an accurate three-dimensional image of the lesion in relation to the root anatomy. Cohenca et al. in 2007 concluded that CBCT was extremely useful for diagnosing the degree of root resorption, determining subsequent treatment. Internal root defects, such as resorption, can perforate the external surface, and this may not be detectable by conventional radiographic techniques. The test should be done during diagnosis and treatment planning. The main limitation of conventional radiographic techniques is that a two-dimensional image can only provide limited clinical information regarding three-dimensional structures. The CBCT provides additional information about the location and nature of the root. With the low effective doses, and the relevant additional information provided, the use of CBCT scanners is justified in the management of complex endodontic problems. The results of images obtained by CBCT can modify the treatment planning, as well as the techniques that can be used during a surgical or non-surgical endodontics [37, 38].

#### 4.6 The diagnosis of cystic lesions and non-endodontic pathology

The diagnosis of cystic lesions is very important because there is controversy about these lesions and the curation without surgical treatment, since cysts can only be diagnosed histologically, which needs surgical excision. Different studies have tried to differentiate between granuloma and cysts through radiographs, based on the different densities of the contents of the cavity. Simon et al. in 2006 using CBCT found that the diagnosis coincided with the histological examination in 13 of the 17 cases studied [39]. However, Rosenberg et al. in 2010 about 45 cases, concluded that the diagnosis did not could be confirmed with CBCT [40]. Other studies should be

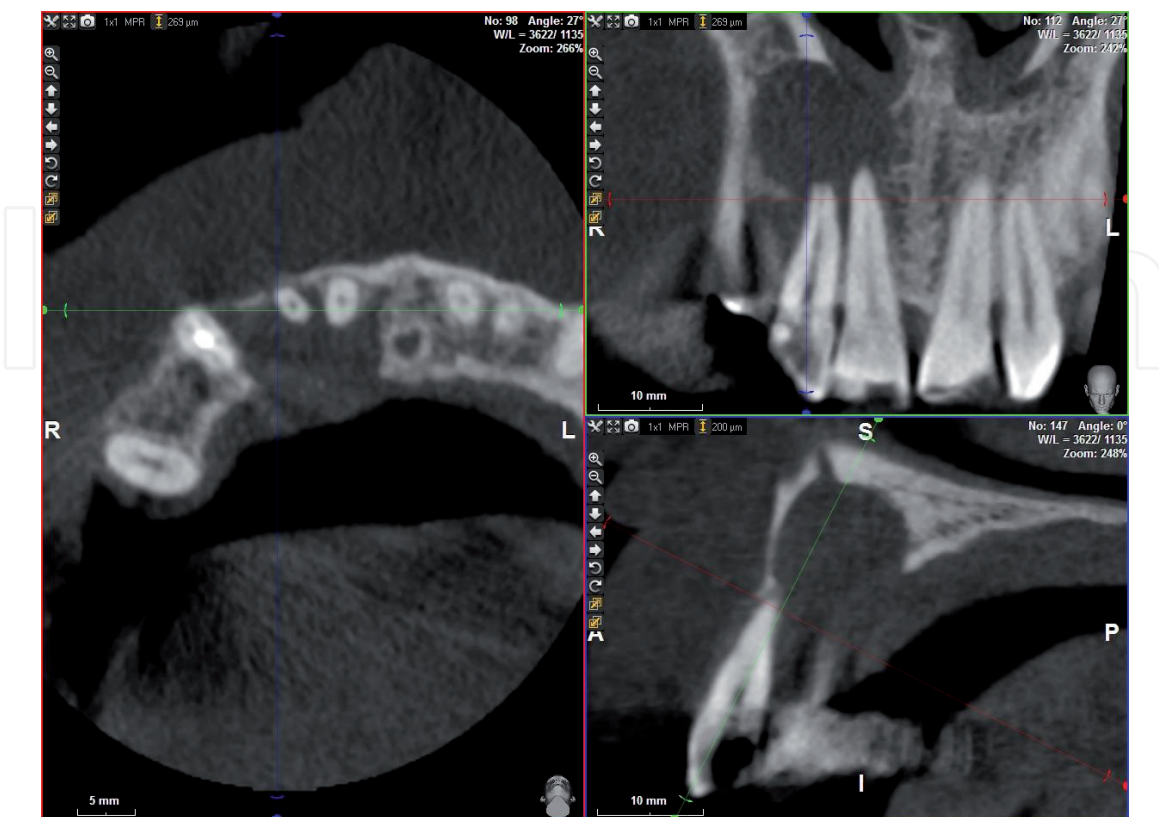

Figure 6.  
*Cyst lesion and adjacent tissues affected.*

carried out to determine the diagnostic capacity of CBCT in these cases. Successful endodontic treatment depends on the correct identification of all root canals; this allows shaping, cleaning and filling.

Non-identification of the anatomy is one of the main causes of endodontic failure. Matherne et al. in 2008 compared the ability of three board-certified endodontists to detect the number of root canals on intraoral digital radiographs and CBCT images on 72 teeth extracted in 3 equal groups of upper molars, lower premolars and mandibular incisors. The observers could not detect at least one of the root canals in 40% of the teeth using 2D images, which demonstrate the advantage of CBCT over conventional radiology [41]. (Figure 6).

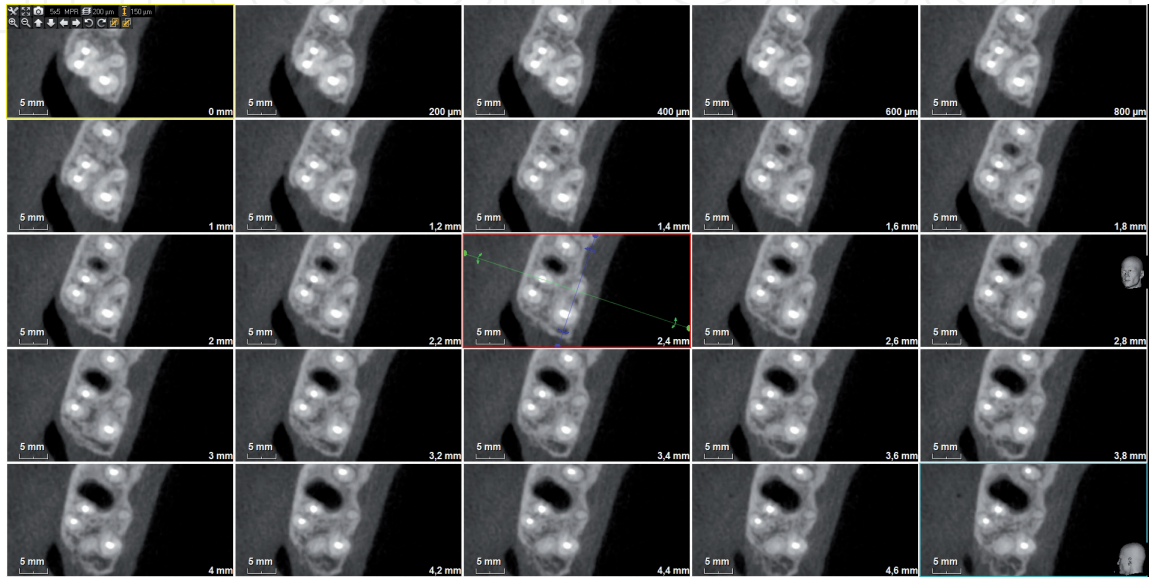


Figure 7.  
*Patient with second untreated palatine canal.*

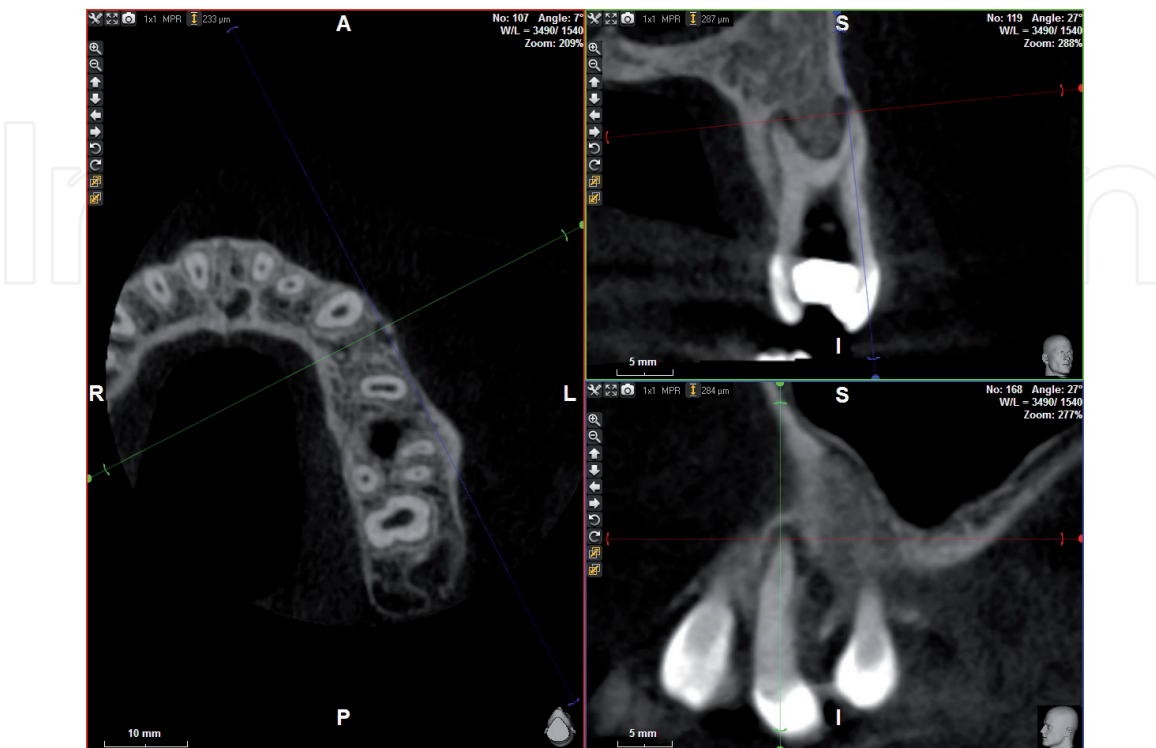


Figure 8.  
*Upper premolar with presence of taurodontism.*



## 4.7 Recommendations

Following the consensus documents prepared by the American Association of Endodontics and the European Society of Endodontics, some recommendations are established for the use of CBCT in endodontics. The first recommendation states that intraoral radiography should be the choice for endodontic treatment, while a small field CBCT would be recommended for those patients with confused or nonspecific signs with untreated teeth or with previous endodontic treatments (**Figure 7**). They also recommend that CBCT could be considered for those teeth that are more likely to have complex anatomies or accessory root canals, (**Figure 8**) also if a CBCT has not been taken before, it could be considered to locate calcified root canals. However, for postoperative follow-up, the treatment of choice should be intraoral radiography. When the possibility of a vertical fracture is suspected if the need for CBCT can be considered, the same as when an injury does not heal and we have to consider the possibility of periapical surgery and when we find perforations or separate instruments before carry out a retreat; it is also recommended when we need to assess the proximity of delicate anatomical areas as well as for the management of dento-alveolar trauma in the absence of soft tissue damage or maxillofacial involvement [42, 43].

## 5. Conclusions

The help of CBCT technology in the diagnosis of endodontics either in the knowledge of the morphology and pathologies of the root canal system, in the evaluation of root and alveolar fractures, in the analysis of resorption, in the identification of pathologies of non-endodontic origin and in pre-surgical assessment, it is a very valuable method. Exact data lead to better treatment planning decisions giving more predictable results.

When comparing medical CT with CBCT it is verified that the accuracy has been increased, a higher resolution is obtained, the reduction of the exposure time, a reduction of the radiation and a lower cost for the patient is achieved.

Compared to conventional periapical radiography, CBCT eliminates the overlapping of surrounding structures by providing additional clinically relevant information.

Conventional two-dimensional radiographs remain the most accepted and used in endodontics imaging modality. These limitations arise mainly due to the inherent projection of a three-dimensional anatomy, which leads to geometric distortions and, consequently, misinterpretation.

Despite the obvious advantages of CBCT technology offered in the field of dentistry, there are some drawbacks and limitations as there is a growing concern among radiologists and maxillofacial about the increase in radiation on patients, in addition to the interpretation of these images require extensive knowledge of various structures. Because accurate diagnostic information leads to better clinical results, CBCT could prove to be a very valuable tool in modern endodontic practice [44].

CBCT's relatively modern technology has added another dimension to dental radiography and is rapidly becoming the gold standard for radiographic inspections in dentistry. At present, it cannot replace periapical radiography due to cost reasons and the degree of effective radiation [45]. However the techniques will improve to reduce the radiation dose and costs. CBCT currently has a reference place in endodontics, where the increase in the number of complex cases justifies the use of technology and the benefits to the patient are greater than the risks.

IntechOpen

IntechOpen

### **Author details**

Jesús Mena Álvarez\* and Álvaro Zubizarreta Macho  
Faculty of Health Sciences, Alfonso X El Sabio University, Madrid, Spain

\*Address all correspondence to: [jmenaalvarez@gmail.com](mailto:jmenaalvarez@gmail.com)

### **IntechOpen**

---

© 2020 The Author(s). Licensee IntechOpen. This chapter is distributed under the terms of the Creative Commons Attribution License (<http://creativecommons.org/licenses/by/3.0>), which permits unrestricted use, distribution, and reproduction in any medium, provided the original work is properly cited. 

## References

- [1] Tamse A, Kaffe I, Fishel D. Zygomatic arch interference with correct radiographic diagnosis in maxillary molar endodontics. *Oral Surgery*. 1980;**50**:563-565
- [2] Patel S, Kanagasingam S, Mannocci F. Cone beam computed tomography (CBCT) in endodontics. *Dental Update*. 2010;**37**(6):373-379
- [3] Farman AG, Levato CM, Scarfe WC. 3D X-ray: An update. *Inside Dentistry*. 2007;**3**(6):70-74
- [4] Feldkamp LA, Davis LC, Kress JW. Practical cone beam algorithm. *Journal of the Optical Society of America. A*. 1984;**1**(6):612-619
- [5] Scarfe WC, Levin MD, Gane D, Farman AG. Use of cone beam computed tomography in endodontics. *International Journal of Dentistry*. 2009;**2009**:634567. DOI: 10.1155/2009/634567. Epub 31 March 2010
- [6] Kiarudi AH, Eghbal MJ, Safi Y, Aghdasi MM, Fazlyab M. The applications of cone-beam computed tomography in endodontics: A review of literature. *Iranian Endodontic Journal*. 2015;**10**(1):16-25
- [7] Tyndall DA, Rathore S. Cone-beam CT diagnostic applications: Caries, periodontal bone assessment, and endodontic applications. *Dental Clinics of North America*. 2008;**52**(4):825-841
- [8] Durack C, Patel S. Cone beam computed tomography in endodontics. *Brazilian Dental Journal*. 2012;**23**(3):179-191
- [9] Moshiri M, Scarfe WC, Hilgers ML, Scheetz JP, Silveira AM, Farman AG. Accuracy of linear measurements from imaging plate and lateral cephalometric images derived from cone-beam computed tomography. *American Journal of Orthodontics and Dentofacial Orthopedics*. 2007;**132**:550-560
- [10] Pauwels R, Beinsbergera J, Collaert B, Theodorakou C, Rogerse J, Walker A, et al. Effective dose range for dental cone beam computed tomography scanners. *European Journal of Radiology*. 2012;**81**(2):267-271
- [11] Ludlow JB, Davies-Ludlow LE, Brooks SL, Howerton WB. Dosimetry of 3 CBCT devices for oral and maxillofacial radiology: CB Mercuray, NewTom 3G and i-CAT. *Dento Maxillo Facial Radiology*. 2006;**35**(4):219-226
- [12] Abella F, Patel S, Durán-Sindreu F, Mercadé M, Bueno R, Roig M. Evaluating the periapical status of teeth with irreversible pulpitis by using cone-beam computed tomography scanning and periapical radiographs. *Journal of Endodontics*. 2012;**38**(12):1588-1591
- [13] Ball RL, Barbizam JV, Cohenca N. Intraoperative endodontic applications of cone-beam computed tomography. *Journal of Endodontics*. 2013;**39**(4):548-557
- [14] Bhuva B, James JJ, Patel S. The use of limited cone beam computed tomography in the diagnosis and management of a case of perforating internal root resorption. *International Endodontic Journal*. 2011;**44**:777-786
- [15] Bender IB, Seltzer S. Roentgenographic and direct observation of experimental lesions in bone. Part I. *Journal of the American Dental Association* (1939). 1961;**62**:152-160
- [16] Bender IB, Seltzer S. Roentgenographic and direct observation of experimental lesions in bone. Part II. *Journal of the*



- American Dental Association (1939). 1961;**62**:708-716
- [17] Goldman M, Pearson AH, Darzenta N. Endodontic success - Who's reading the radiograph. *Oral Surgery*. 1972;**33**:432-437
- [18] Levin LG, Law AS, Holland GR, Abbott PV, Roda RS. Identify and define all diagnostic terms for pulpal health and disease states. *Journal of Endodontics*. 2009;**35**:1645-1657
- [19] Estrela C, Bueno MR, Leles CR, Azevedo B, Azevedo JR. Accuracy of cone beam computed tomography and panoramic and periapical radiography for detection of apical periodontitis. *Journal of Endodontics*. 2008;**34**(3):273-279
- [20] Lofthag-Hansen S, Huuemonen S, Gröndahl K, Gröndahl H. Limited cone-beam CT and intra oral radiography for the diagnosis of periapical pathology. *Oral Surgery, Oral Medicine, Oral Pathology, Oral Radiology, and Endodontics*. 2007;**103**:114-119
- [21] Low K, Dula K, Bürgin W, von Arx T. Comparison of periapical radiography and limited cone-beam tomography in posterior maxillary teeth referred for apical surgery. Identification of root morphology and canal anatomy. *Journal of Endodontics*. 2008;**34**(5):557-562
- [22] Cotton TP, Geisler TM, Holden DT, Schwartz SA, Schindler WG. Endodontic applications of cone-beam volumetric tomography. *Journal of Endodontics*. 2007;**33**(9):1121-1132
- [23] Garcia de Paula-Silva F, Hassan B, Bezerra da Silva L, Leonardo M, Wu M. Outcome of root canal treatment in dogs determined by periapical radiography and cone-beam computed tomography scans. *Journal of Endodontics*. 2009;**35**(5):723-726
- [24] de Paula-Silva FW, Santamaria M Jr, Leonardo MR, Consolaro A, da Silva LA. Cone-beam computerized tomographic, radiographic, and histologic evaluation of periapical repair in dogs' postendodontic treatment. *Oral Surgery, Oral Medicine, Oral Pathology, Oral Radiology, and Endodontics*. 2009;**108**(5):796-805
- [25] Tamse A, Fuss Z, Lustig J, Kaplavi J. An evaluation of endodontically treated vertically fractured teeth. *Journal of Endodontics*. 1999;**25**:506-508
- [26] Cohen S, Berman LH, Blanco L, Bakland L, Kim JS. A demographic analysis of vertical root fractures. *Journal of Endodontics*. 2006;**32**:1160-1163
- [27] Hannig C, Dullin C, Hülsmann M, Heidrich G. Three-dimensional, non-destructive visualization of vertical root fractures using flat panel volume detector computer tomography: An ex vivo in vitro case report. *International Endodontic Journal*. 2005;**38**(12):904-913
- [28] Rud J, Omnell K. Root fractures due to corrosion. Diagnostic aspects. *Scandinavian Journal of Dental Research*. 1970;**78**(5):397-403
- [29] Edlund M, Nair M, Nair U. Detection of vertical root fractures by using cone-beam computed tomography: A clinical study. *Journal of Endodontics*. 2011;**37**(6):768-772
- [30] Gassner R, Bosch R, Emshoff R. Prevalence of dental trauma in 6000 patients with facial injuries: Implications for prevention. *Oral Surgery, Oral Medicine, Oral Pathology, Oral Radiology*. 1999;**87**:27-33
- [31] Bernardes RA, de Moraes IG, Hungaro Duarte MA, Azevedo BC, de Azevedo JR, Bramante CM. Use of cone-beam volumetric tomography in

the diagnosis of root fractures. *Oral Surgery, Oral Medicine, Oral Pathology, Oral Radiology, and Endodontics*. 2009;**108**(2):270-277

[32] Cotti E, Vargiu P, Dettori C, Mallarini G. Computerized tomography in the management and follow-up of extensive periapical lesion. *Endodontics & Dental Traumatology*. 1999;**15**:186-189

[33] Velvart P, Hecker H, Tillinger G. Detection of the apical lesion and the mandibular canal in conventional radiography and computed tomography. *Oral Surgery, Oral Medicine, Oral Pathology and Endodontology*. 2001;**92**:682-688

[34] Rigolone M, Pasqualini D, Bianchi L, Berutti E, Bianchi SD. Vestibular surgical access to the palatine root of the superior first molar: "low-dose cone-beam" CT analysis of the pathway and its anatomic variations. *Journal of Endodontics*. 2003;**29**:773-775

[35] Shemesh H, Cristescu RC, Wesselink PR, Wu M. The use of cone-beam computed tomography and digital periapical radiographs to diagnose root perforations. *Journal of Endodontics*. 2011;**37**(4):513-516

[36] Gartner AH, Mack T, Somerlott RG, Walsh LC. Differential diagnosis of internal and external root resorption. *Journal of Endodontics*. 1976;**2**:329-334

[37] Cohenca N, Simon JH, Roges R, Morag Y, Malfaz JM. Clinical indications for digital imaging in dento-alveolar trauma. Part 1: Traumatic injuries. *Dental Traumatology*. 2007;**23**:95-104

[38] Cohenca N, Simon JH, Marhtur A, Malfaz JM. Clinical indications for digital imaging in dento-alveolar trauma. Part 2: Root resorption. *Dental Traumatology*. 2007;**23**:105-113

[39] Simon JH, Enciso R, Malfaz J-M, Roges R, Bailey-Perry M, Patel A. Differential diagnosis of large periapical lesions using cone-beam computed tomography measurements and biopsy. *Journal of Endodontics*. 2006;**32**:833-837

[40] Rosenberg PA, Frisbie J, Lee J, Lee K, Frommer H, Kottal S, et al. The Journal of Endocrinology. 2010;**36**(3):423-428

[41] Matherne RP, Angelopoulos C, Kulild JC, Tira D. Use of CBCT to identify root canal systems in vitro. *Journal of Endodontics*. 2008;**34**:87-89

[42] AAE and AAOMR Joint position statement: Use of cone beam computed tomography in endodontics 2015 update. *Journal of Endodontics*. 2015;**41**(9):1393-1396. DOI: 10.1016/j.joen.2015.07.013

[43] Patel S, Durack C, Abella F, Roig M, Shemesh H, Lambrechts P, et al. European society of endodontology position statement: The use of CBCT in endodontics. *International Endodontic Journal*. 2014;**47**(6):502-504

[44] Kaya S, Yavuz I, Uysal I, Akkus Z. Measuring bone density in healing periapical lesions by using cone beam computed tomography: A clinical investigation. *Journal of Endodontics*. 2012;**38**(1):28-31

[45] Martin Palomo J, Rao PS, Hans MG. Influence of CBCT exposure conditions on radiation dose. *Oral Surgery, Oral Medicine, Oral Pathology, Oral Radiology, and Endodontics*. 2008;**105**:773-782